

Case reports

Spinal segmental myoclonus related to pregnancy

Deniz YERDELEN¹, Mehmet KARATAŞ¹, Erdoğan ASLAN², Semih GIRAY¹ and Meliha TAN¹

¹Department of Neurology, ²Department of Obstetrics and Gynecology, Baskent University Faculty of Medicine, Ankara, Turkey

Abstract

A 33-year-old pregnant woman (gestational age, 39 weeks and 2 days) presented with a one-day history of abdominal rhythmic myoclonus. Gynecological examination revealed that the cervix was unfavorable with irregular contractions that were ineffective. Electroencephalography, MRI of the dorsal spine and blood biochemical examinations were normal. Electrophysiological recordings from the rectus abdominis muscles with surface electrodes showed 2 Hz rhythmic myoclonic activity bursts. On the same day, the delivery was induced and the frequency and severity of involuntary contractions decreased and disappeared in two days. This is the first case of abdominal myoclonus developed as a complication of pregnancy or delivery.

Key words : spinal segmental myoclonus ; pregnancy.

Table 1

Possible causes of spinal myoclonus (4, 5)

- | |
|-----------------------------------|
| 1. Arterio-venous malformation |
| 2. Myelitis |
| 3. Intradural tumour or cyst |
| 4. Spondylosis |
| 5. Radiculopathies |
| 6. Spinal anaesthesia |
| 7. Laparotomy |
| 8. Radiotherapia |
| 9. Paraneoplastic syndrome |
| 10. Syringomyelia |
| 11. Trauma |
| 12. Multiple sclerosis |
| 13. Amyotrophic lateral sclerosis |
| 14. Viral infection |

Introduction

Myoclonus is defined as sudden, brief, shock-like, involuntary movement due to either active muscular contraction or inhibition of muscle activity (1). Its source of origin may be cortical, subcortical or spinal (2). Segmental myoclonus is characterized by myoclonic involvement of a muscle or a group of muscles supplied by a few contiguous brain stem or spinal cord segments (3). There are several possible causes of spinal myoclonus (Table 1) (4, 5).

Here we present a case of spinal segmental myoclonus in a pregnant woman close to the end of the third trimester.

Case report

A-33-year-old pregnant woman (gestational age, 39 weeks and 2 days at the time of admission) presented with a one-day history of sudden onset involuntary contractions of the abdominal muscles. She had these involuntary movements while awake or asleep without loss of consciousness or sphincteric disturbances. This presentation was the first occurrence, and there was no significant previous medical history nor family history of neurological illness. She had not used any drugs in the past or recently.

General physical examination was normal apart from pregnancy. In gynecological examination, the cervix was unfavorable, with irregular contractions that were ineffective. Neurological examination revealed bilateral rhythmic myoclonus of the abdominal muscles and any other pathological findings could be encountered. The rate and amplitude of involuntary movements were increased by emotional stress.

Routine biochemical examinations including serum urea, creatinine, liver function tests, Na, K, and vitamin B12, folic acid, calcium, magnesium, and thyroid function tests were normal. Complete blood count showed mild anemia (hematocrit : 34.1%, hemoglobin :10.5 gr/dl, MCV : 85.4 fl). Electroencephalography (EEG) was normal. Magnetic resonance imaging of the thoracal and lumbar spine were normal. Electrophysiological recordings with surface electrodes showed rhythmic, myoclonic activity bursts with a rate of 2 Hz in bilaterally rectus abdominis muscles, dominant in the left. The duration and amplitude of the EMG bursts were 80-100 milliseconds and 50-300 microvolts, respectively (Fig. 1).

After the assessment of fetal well being by cardiotocography and biophysical scoring, it was decided to induce the delivery by 0.25 microgram misoprostol applied per vagina and, after adequate cervical ripening, instituted IV oxytocin infusion

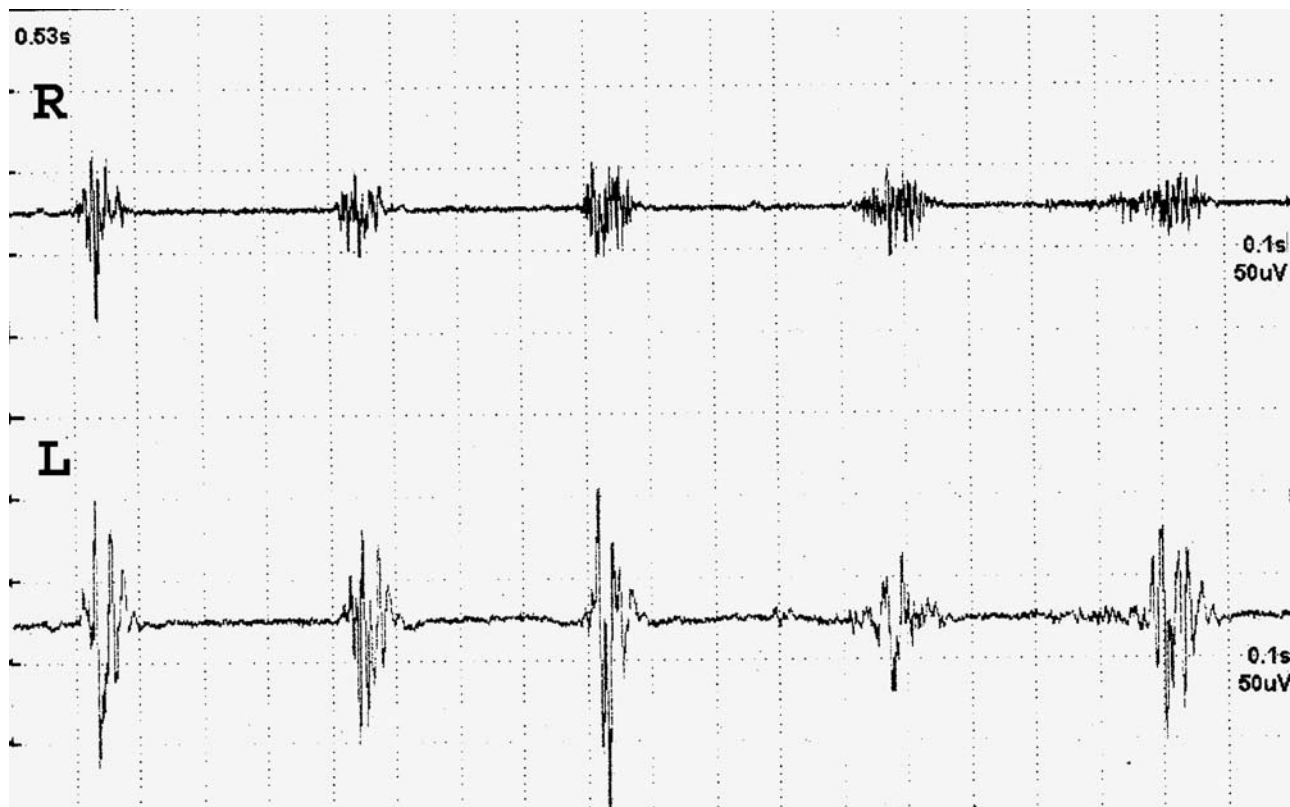


FIG. 1. — Rhythmic, myoclonic activity. Bursts with a frequency of 2 Hz and dominant on the left were recorded with surface electrodes from bilateral rectus abdominis muscles.

according to the hospital protocol. A female baby, weighing 3700 gr was delivered vaginally after 8 hours of labour. Antenatal follow-up was also uneventful. After labour, the frequency and severity of involuntary contractions decreased and disappeared within two days. This condition did not recur.

Discussion

Myoclonus may be classified as cortical, subcortical, cortical-subcortical, segmental, or peripheral in origin (2, 6). In the segmental type, the distribution of muscle jerking is limited to muscles innervated by one or more contiguous spinal segments. The term 'spinal segmental myoclonus' refers to segmental myoclonus originating from the spinal cord. This rare type of myoclonus is usually rhythmic and slow (< 4 Hz) (6).

The pathophysiology of spinal myoclonus remains speculative. Various possible mechanisms have been suggested including loss of inhibitory function of local dorsal horn interneuron, abnormal hyperactivity of local anterior horn cell, aberrant local axons re-excitation and loss of inhibition from suprasegmental descending pathways (3). However aetiology and pathogenetic mechanism could not be fully explained. On the other hand,

several possible causes of spinal myoclonus have already been described (Table 1). The aetiology of spinal myoclonus frequently remains unknown (4, 6, 7, 8).

Our patient had been pregnant for 39 weeks and 2 days. She had rhythmic bilaterally abdominal muscle contractions, but these were unrelated with delivery event. The cervix was unfavorable and the contractions were not like those from smooth muscles. Electrophysiological recordings of rectus abdominis muscles were compatible with rhythmic, myoclonic activity bursts with a rate of 2 Hz. EEG and MRI of the thoraco-lumbar spinal cord were normal. No explanatory pathological laboratory findings could be found. The enlarged uterus in the later stages of pregnancy is expected to affect the vascular circulation of the spinal cord (9). Dilated veins, compressing the roots, have also been reported during pregnancy (10). We speculate that the possible cause of abdominal myoclonus in this pregnant woman may be impaired spinal cord circulation due to intraabdominal vascular compression by mass effect. Decreasing and then termination of involuntary contractions in two days after delivery also support this suggestion.

According to the literature data, this is the first case of spinal segmental myoclonus developing during pregnancy and disappearing after labour.

REFERENCES

1. CAVINESS J. N. Myoclonus. *Mayo Clin. Proc.*, 1996, **71** : 679-688.
2. SHIBASAKI H., HALLETT M. Electrophysiological studies of myoclonus. *Muscle Nerve*, 2005, **31** : 157-174.
3. JANKOVIC J., PARDO R. Segmental myoclonus. *Arch. Neurol.*, 1986, **43** : 1025-1031.
4. RAY B. K., GUHA G., MISRA A. K., DAS S. K. Involuntary jerking of lower half of the body (spinal myoclonus). *J. Assoc. Physicians India*, 2005, **53** : 141-3.
5. CELIK Y., BEKIR DEMIREL C., KARACA S., KOSE Y. Transient segmental spinal myoclonus due to spinal anesthesia with bupivacaine. *J. Postgrad. Med.*, 2003, **49** : 286.
6. CAMPOS C. R., LIMONGI J. C., MACHADO F. C., BROTTO M. W. A case of primary spinal myoclonus : clinical presentation and possible mechanisms involved. *Arq. Neuropsiquiatr.*, 2003, **61** : 112-4.
7. TSAO J. W., COOPER E. C. Reflex-sensitive spinal segmental myoclonus associated with vitamin B12 deficiency. *Neurology*, 2003, **61** : 867-8.
8. LÖSCHER W. N., TRINKA E. Late delayed post-radiation spinal myoclonus or psychogenic movement disorder ? *Movement Disorders*, 2003, **18** : 346-9.
9. HIRABAYASHI Y., SHIMIZU R., FUKUDA H., SAITOH K., IGARASHI T. Effects of the pregnant uterus on the extradural venous plexus in the supine and lateral positions, as determined by magnetic resonance imaging. *Br. J. Anaesth.*, 1997, **78** : 317-9.
10. GORMUS N., USTUN M. E., PAKSOY Y., OGUN T. C., SOLAK H. Acute thrombosis of inferior vena cava in a pregnant woman presenting with sciatica : a case report. *Ann. Vasc. Surg.*, 2005, **19** : 120-2.

Deniz YERDELEN,
Baskent University Faculty of Medicine,
Adana Teaching and Research Center,
Dadaloğlu mah. 39 sok. Yüreğir-Adana (Turkey).
Posta kodu :01250.
E-mail : vahidedenizy@gmail.com.